


Step-by-Step Guide to Slit Lamp Biomicroscopy: A Comprehensive Resource for Ophthalmic Professionals

Slit lamp biomicroscopy is a fundamental technique in ophthalmology, providing a detailed examination of the anterior segment of the eye. This invaluable procedure enables eye care professionals to diagnose and manage a wide range of ocular conditions. The Step-by-Step Guide to Slit Lamp Biomicroscopy offers a comprehensive resource for ophthalmologists, optometrists, and other healthcare professionals seeking to master this essential skill.



MANUAL ON SLIT LAMP BIOMICROSCOPY: A STEP BY STEP GUIDE TO SLIT LAMP BIOMICROSCOPY

by GLADYS .O. GEORGE

★★★★☆ 4 out of 5

Language : English

File size : 1820 KB

Screen Reader : Supported

Print length : 23 pages

Lending : Enabled



Section 1: Basic Principles

This section lays the foundation for understanding the principles of slit lamp biomicroscopy. It covers topics such as:

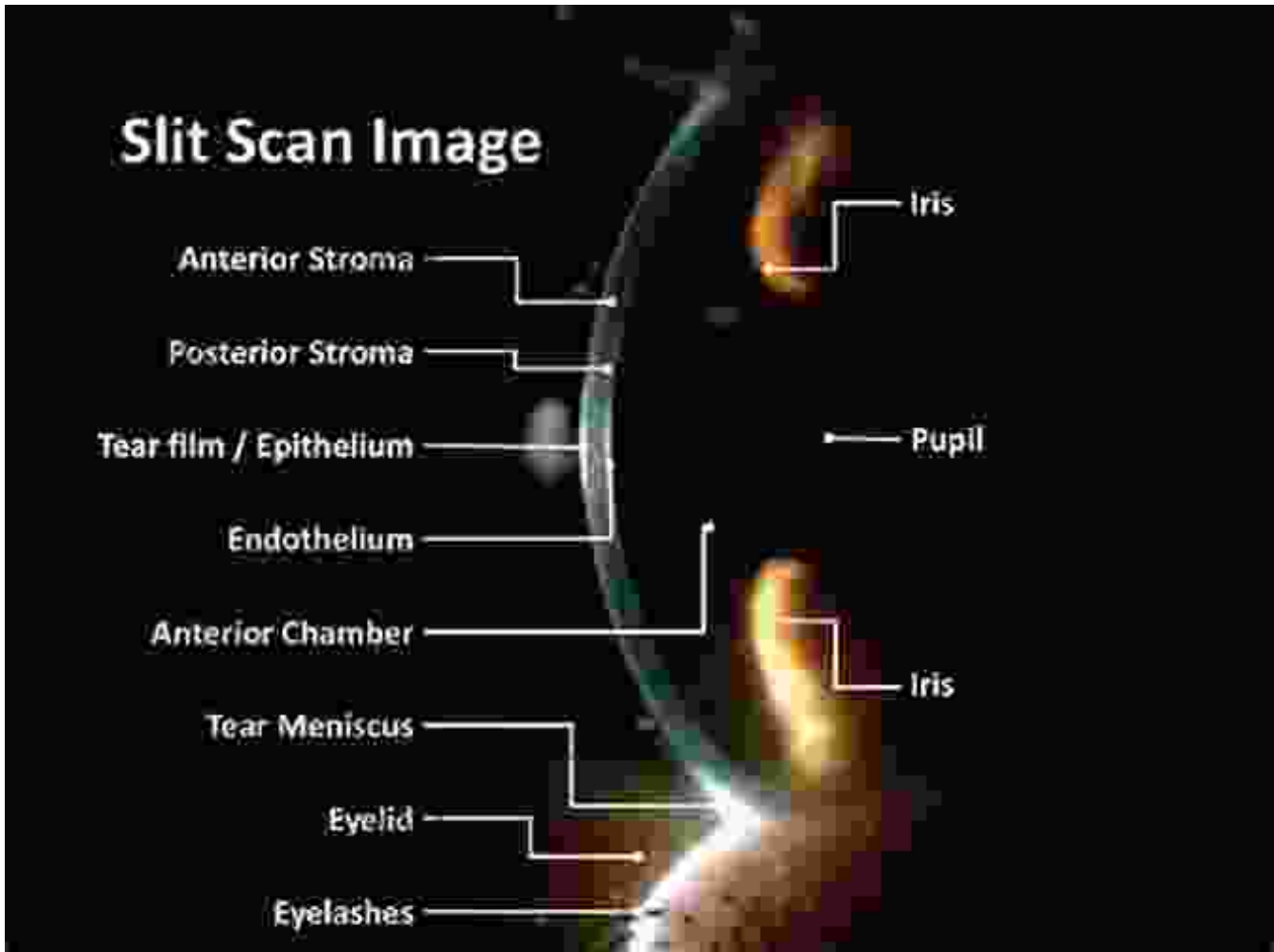
- Anatomy of the anterior segment of the eye

- Principles of illumination and magnification
- Types of slit lamps and their components
- Patient positioning and examination techniques

Section 2: Examination of the Cornea

The cornea is the transparent outer layer of the eye, playing a crucial role in vision. Section 2 provides a thorough examination of the cornea, including:

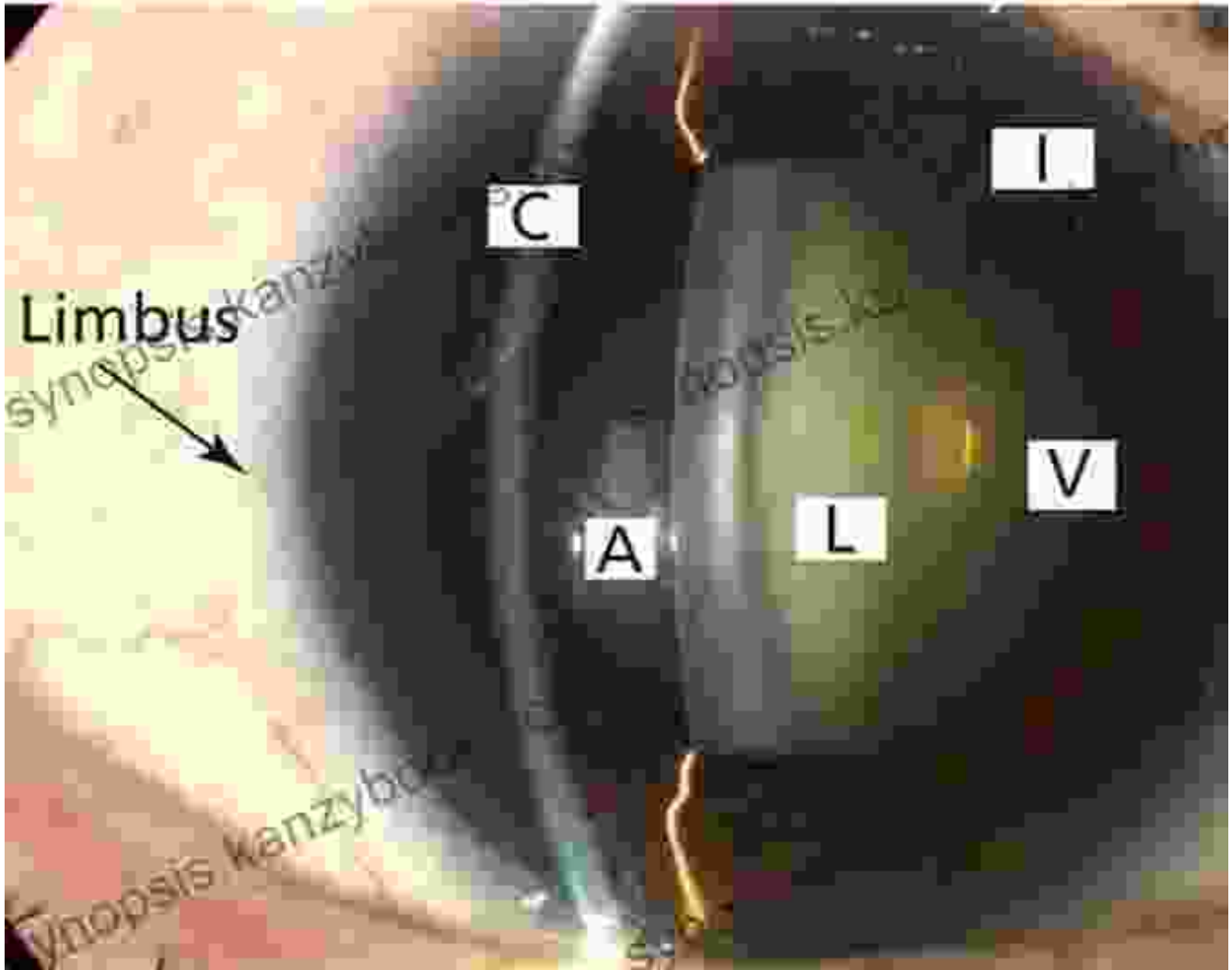
- Assessment of corneal clarity and thickness
- Detection of corneal abnormalities such as ulcers, scars, and infections
- Measurement of corneal curvature
- Evaluation of corneal endothelium



Section 3: Examination of the Anterior Chamber

The anterior chamber is the fluid-filled space between the cornea and the iris. Section 3 guides readers through the examination of this important area, covering:

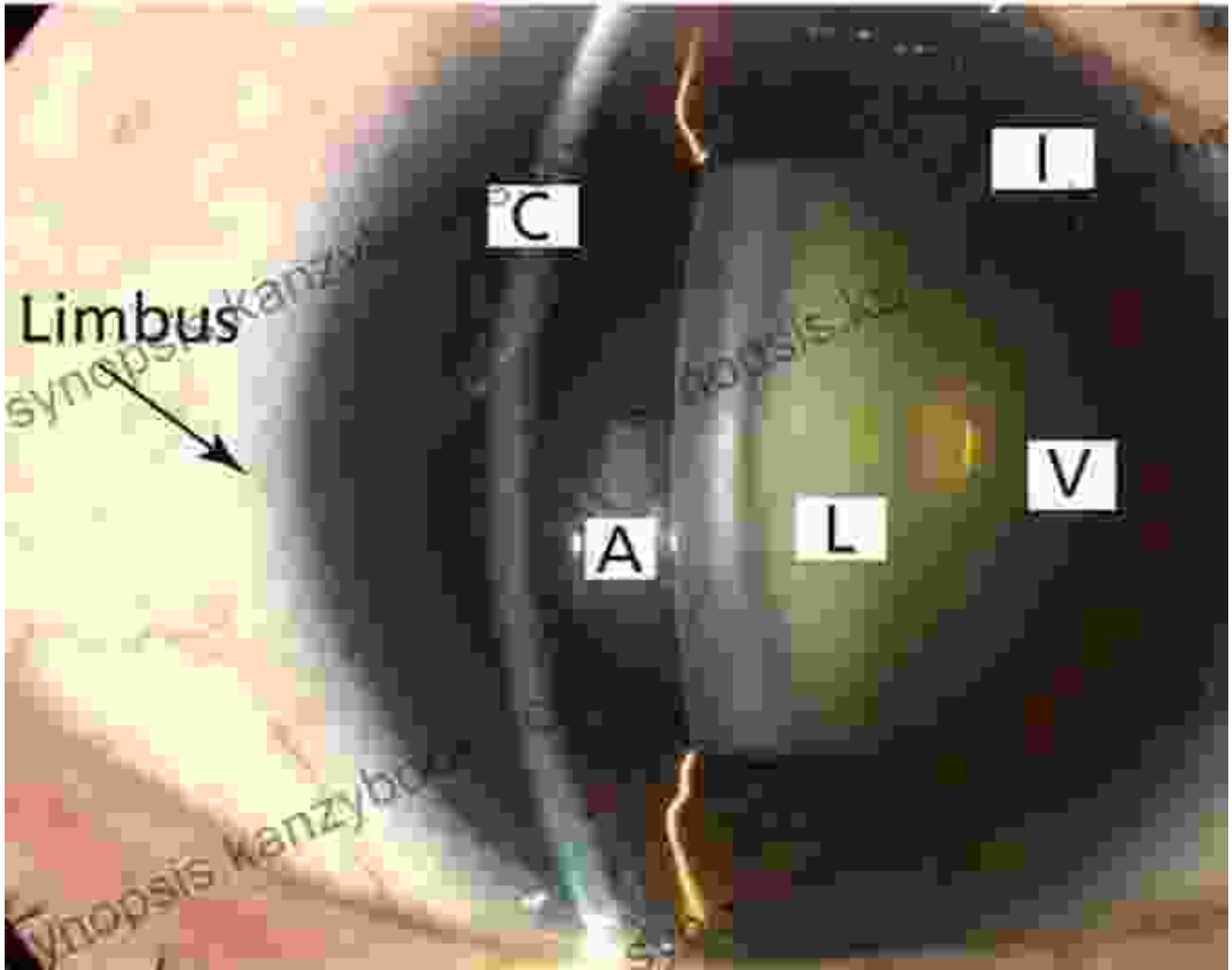
- Assessment of anterior chamber depth
- Detection of cells, flare, and other inflammatory signs
- Evaluation of the iris and pupillary reflexes
- Assessment of the lens



Section 4: Examination of the Vitreous

The vitreous is the gel-like substance that fills the posterior chamber of the eye. Section 4 describes the techniques for examining the vitreous, including:

- Assessment of vitreous clarity and consistency
- Detection of vitreous opacities, such as floaters and cells
- Evaluation of the vitreous-retinal interface

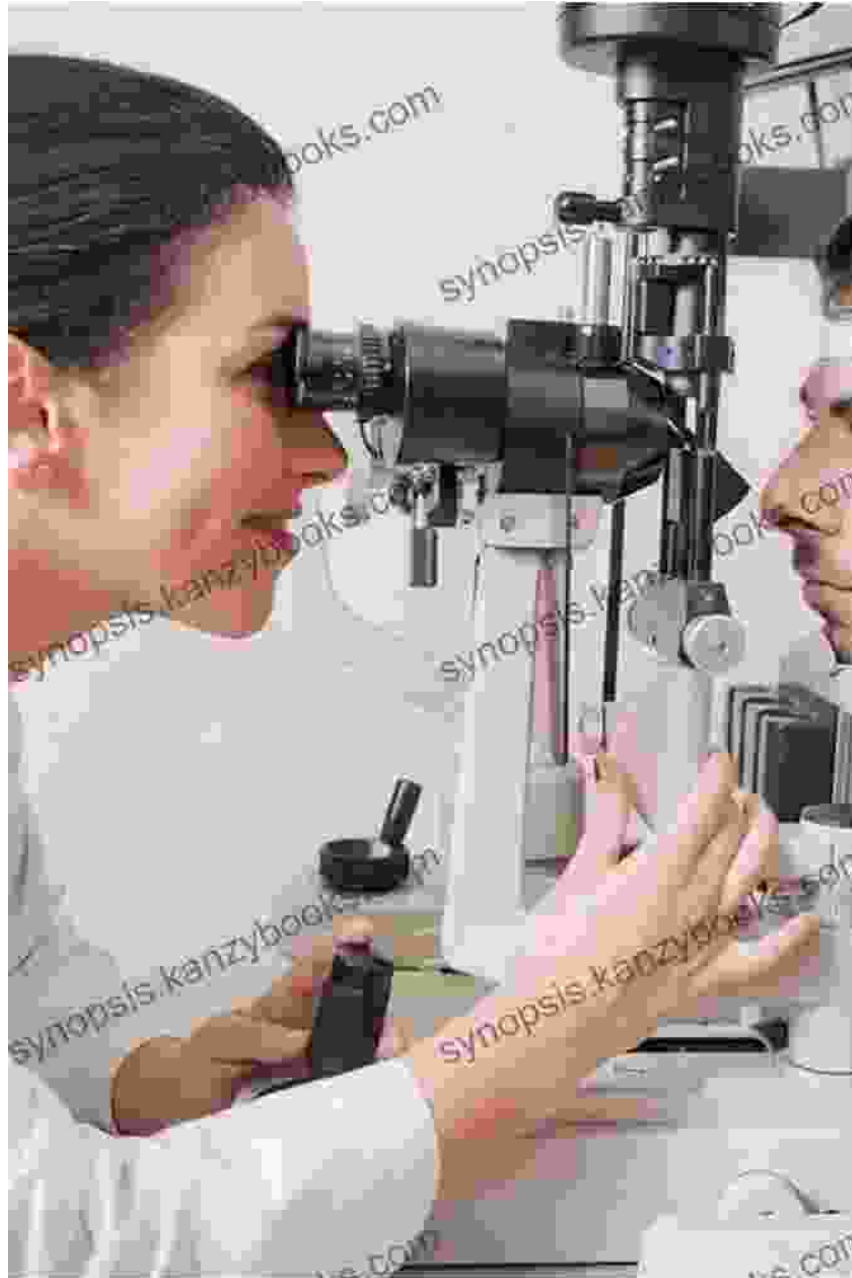

Section 5: Examination of the Fundus

The fundus refers to the posterior segment of the eye, including the retina, optic disc, and blood vessels. Section 5 provides a comprehensive guide to fundus examination, covering:

- Assessment of retinal structure and pigmentation
- Detection of retinal abnormalities, such as macular degeneration and diabetic retinopathy
- Evaluation of the optic nerve head


- Assessment of retinal blood vessels



The Step-by-Step Guide to Slit Lamp Biomicroscopy is an indispensable resource for ophthalmic professionals seeking to master this essential technique. Its comprehensive approach, clear explanations, and detailed illustrations provide a solid foundation for successful anterior segment examinations. By following the guidance provided in this book, eye care

professionals can enhance their diagnostic accuracy, improve patient care, and contribute to the preservation of vision.

To Free Download your copy of the Step-by-Step Guide to Slit Lamp Biomicroscopy, please visit our website or contact your preferred medical bookstore.



MANUAL ON SLIT LAMP BIOMICROSCOPY: A STEP BY STEP GUIDE TO SLIT LAMP BIOMICROSCOPY

by GLADYS .O. GEORGE

★ ★ ★ ★ ☆ 4 out of 5

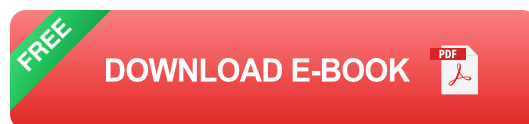
Language : English

File size : 1820 KB

Screen Reader: Supported


Print length : 23 pages

Lending : Enabled



Unveiling the Tapestry of Human History: Archaeology, History, and Ethnography

Embark on an extraordinary journey through time and across cultures with the captivating book, "Archaeology, History, and Ethnography." This masterpiece unravels the...



Meditations On Living, Dying, And Loss: A Journey Through Life's Profound Transitions

In the tapestry of human existence, life, death, and loss are inseparable threads, interwoven into an intricate and enigmatic dance. Our journey through this mortal realm...